



PRESENTING CLINICAL SIGNS

History: Decreased appetite, lethargy. Distended abdomen. Thoracic radiographs show a possible opacity in the cranial mediastinum. In the lateral images, though this is not visible in the VD image.

DATE

1/23/23

ECHOCARDIOGRAPHIC FINDINGS

2D, M-mode, and Doppler study.

PERFORMED BY:

Amy Mayhew, LVT

INTERPRETED BY

Keith Blass, DVM,
MS, DACVIM
(Cardiology)

Left atrial size is normal. The mitral valve is normal. Left ventricular wall thickness is normal. Left ventricular internal dimensions are normal. Left ventricular systolic function is hyperdynamic. The aorta and aortic valve are normal. Right atrial and right ventricular dimensions are normal. The tricuspid valve is normal. The pulmonary artery and pulmonic valve are normal. No shunting lesions are visualized. No pericardial effusion or cardiac masses are seen. No obvious thoracic masses are visualized.

PATIENT

Little Clark

LA/Ao - 1.49
IVSd - 5.2 mm
LVPWd - 5.0 mm
LVIDd - 14.0 mm
LVIDs - 6.2 mm
FS - 55.7%
RA - 9.9 mm
LVOT - 0.95 m/s
RVOT - 1.21 m/s

SPECIES

Feline

ASSESSMENT/RECOMMENDATIONS

Normal echocardiogram

BREED

This examination demonstrates no evidence of structural heart disease. As such, no reason for Little's lethargy, decreased appetite, and abdominal distension is appreciated in the image set.

DSH

No obvious thoracic/mediastinal masses are visualized in the image set.

SEX

A recheck echocardiogram is recommended if new physical exam and/or clinical abnormalities suggestive of cardiac dysfunction develop.

MN

AGE

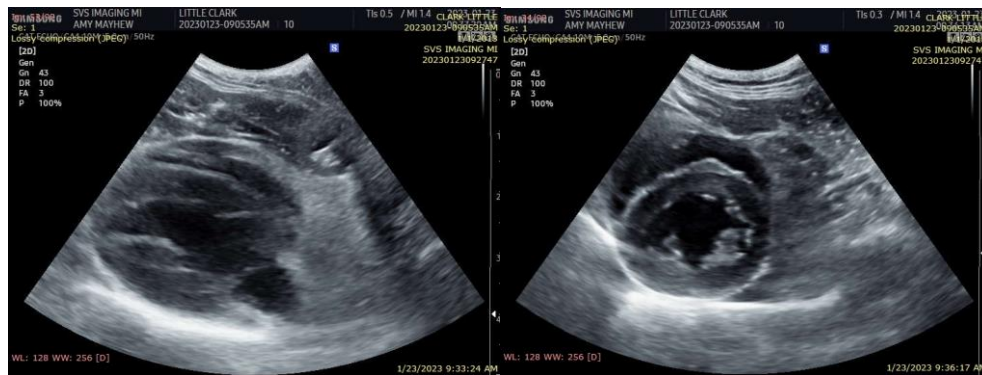
10 y

WEIGHT

15.5 lb

HOSPITAL NAME

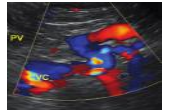
SVS Imaging MI



REFERRING VET

Dr. Fleischaker

The information and recommendations provided are based on the images presented by the



referring veterinarian. No evaluation can be communicated regarding pathology that was not visible in the image/video clips provided.

DATE

1/23/23

Thank you for this referral. If the clinical or image interpretation does not parallel your findings or if I can be of any further assistance please contact me.

PERFORMED BY: Keith Blass, DVM, MS, DACVIM (Cardiology)
KeithBlass@gmail.com
631-804-5754

Amy Mayhew, LVT

INTERPRETED BY

Keith Blass, DVM,
MS, DACVIM
(Cardiology)

PATIENT

Little Clark

SPECIES

Feline

BREED

DSH

SEX

MN

AGE

10 y

WEIGHT

15.5 lb

HOSPITAL NAME

SVS Imaging MI

REFERRING VET

Dr. Fleischaker